

SURGICAL MANAGEMENT OF COMPLETE OBLIQUE COMPOUND FRACTURE OF RADIUS AND ULNA IN AN INDIAN FLYING FOX (*Pteropus giganteus*; Brunnich, 1782)

P. V. Parikh¹, C. M. Bhadesiya^{2*}, Deepak Mer⁴ and Javed Khatri⁴

¹Department of Veterinary Surgery & Radiology, ²Scholar, Department of Veterinary Medicine

³ Department of Veterinary Surgery & Radiology, ⁴Department of Veterinary Surgery & Radiology, College of Veterinary Science & Animal Husbandry, Anand Agricultural University, Anand-388001, Gujarat, India

Corresponding author:- dr.chirag64164@gmail.com

A rescued Indian flying fox (*Pteropus giganteus*; Brunnich, 1782) was brought to College of Veterinary Science & Animal Husbandry, Anand of Gujarat state, India with a history of dropped right wing and an inability to fly. Diagnostic investigation included anamnesis, clinical examination and radiography. The case was confirmed with complete oblique compound fracture of radius and ulna of the right wing. Ketamine and xylazine combination was utilized as surgical anesthesia intramedullary pinning procedure in the affected bones. Post-operative management included use of antibiotic (ceftriaxone and tazobactam combination), non-steroidal anti-inflammatory drug (meloxicam), amino acid supplements and passive range motion physiotherapy. Flying fox recovered uneventfully 21 days post-treatment and was rehabilitated in natural habitat. Since there is a lacuna in diseases and disorders of this species, an effort has been made to utilize available resources to rule out cause of morbidity.

Key words: Indian Flying Fox, Fracture, Radiography, Intramedullary pinning, Rehabilitation

The Indian flying fox (*Pteropus giganteus*; Brunnich, 1782) is classified under Kingdom: *Animalia*, Phylum: *Chordata*, Class: *Mammalia*, Order: *Chiroptera*, Family: *Pteropodidae*, Genus: *Pteropus* and Species: *Pteropus giganteus*. The species has been categorized as least-concerned (lc) by International Union on Conservation of Nature (Molur et al., 2008).

It is also known as the Greater Indian Fruit Bat. It is nocturnal in behavior and is frugivorous or nectarivorous (*i.e.*, feeds mostly on ripened fruits as well as nectar). Common habitats of Indian flying fox include rain forests, swamps nearby a large water body (Tangavelou et al., 2013). The species has been reported to be distributed especially in Bangladesh, Pakistan, Nepal, Bhutan and India in the Asian subcontinent. Little investigations have been made in medicinal and surgical affections of Indian flying fox (McLaughlin et al., 2007). Present report describes surgical management of complete oblique compound fracture of radius and ulna in an Indian flying fox.

MATERIALS AND METHODS

An Indian flying fox (Figure-01) was brought to Department of Veterinary Surgery & Radiology, College of Veterinary Science & Animal Husbandry, Anand with a history of bird being unable to fly with dropped right wing. Flying fox was subjected to a detailed diagnostic approach which included anamnesis, clinical observations, physical examination and radiography.

Anamnesis: Anamnesis revealed that the bird was unable to fly and was hanging on a tree for a period of 3-4 days from where it was rescued. Rescued flying fox was managed on oral rehydration and feeding by the rescuer for few hours after which, it was found that the bird was unable to fly with dropped right wing. There was no evidence of nausea, vomiting, major blood loss, abnormal discharges from orifice.



Figure-01: Rescued Indian flying fox

Clinical examination: Physical examination revealed normothermia, normal respiration, intact left wing, presence of blood clots over radial area on right wing, dropped appearance of right wing, bird being unable to fly.

Radiography: Diagnostic radiography was performed using Horizo-X X-ray machine (Multimobil 2.5, Capacity 40 to 100 kV, 0.32 to 200 mAs, Siemens Ltd.; Plot no. L 6, Verna Industrial Area, Panaji Moragoan Highway, Verna, Goa). Radiograph of the affected (*i.e.*, right) wing was taken in a dorso-ventral position.



Confirmatory Diagnosis: Right wing was reported to have complete oblique compound fracture of radius as well as ulna (Figure-02).

Surgical Procedure: Surgical management was planned for intramedullary pinning following radiographic findings (Redig, 1998). Initial patient stabilization was performed by keeping the bird on heating pad after which, it was injected with a combination of ketamine @ 20mg/kg and xylazine @ 1.5-2.0 mg/kg. A total of 0.12 ml ketamine + xylazine mixture was used for induction. Wound lavage was performed by using warm sterile normal saline solution with 0.5% povidone-iodine solution in order to remove debris and foreign material as well as reduction in bacterial contamination. A 0.5 mm K-wire was used for intramedullary pinning in radius. Retrograde intramedullary pinning was performed initially into the distal fragment of the bone followed by normograde pinning into the proximal fragment. A K-wire with 0.5 mm size was used for this purpose (Figure-03). The surgical incision was closed by simple interrupted sutures using Vicryl 3.0 absorbable suture material. Surgical procedure was followed by post-operative therapeutic management (Lewis et al., 1993). Initial injection of antibiotic was given with ceftiaxome and tazobactam

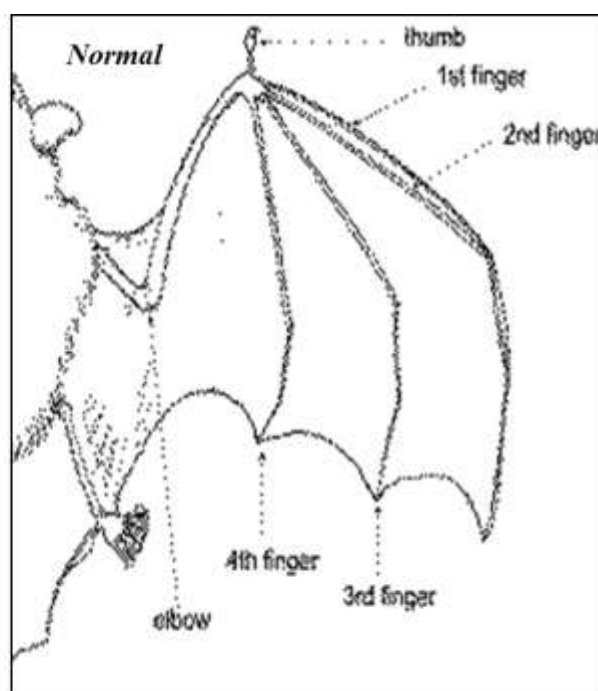


Figure-02: Complete oblique compound fracture on right wing – Radius and ulna

combination @ 25 mg/kg b.wt. intramuscularly which was continued as once daily for 7 consecutive days. Meloxicam oral drop formulation was prescribed to rescuer @ 2-3 drops/day for 5 consecutive days. For improvement in basal metabolism, rescuer was also advised to use syrup containing amino acids @ 2 drops/day for 5 consecutive days. Passive range of motion technique of physiotherapy for the wing after 3-4 days post-operatively was recommended to rescuer.



Figure-03: Intramedullary pin placed inside the fractured segment

RESULTS & DISCUSSION

Rescuer was advised to observe the flying fox for a period of 21 days. The Indian flying fox recovered uneventfully 21 days post-treatment and rehabilitation was planned.

Rehabilitation Procedure: In general most birds fear man more than anything else and unnecessary handling will only jeopardize their survival. As fracture was healed, (Newton & Zeitlin, 1977) rehabilitation was planned out. Rehabilitation becomes an important part of conservation (Tangavelou et al., 2013). A cardboard box with proper ventilation and of a suitable size to accommodate the flying fox was used for this purpose. A restraining towel was placed over the bird to place the bird inside the cardboard box. The box was then kept in quiet, dark and warm area. Provision only of fresh water was preferred to avoid possibilities of nausea or vomiting during transport. The Indian flying fox was rehabilitated successfully on 21st day post-surgical procedure in its natural habitat.

CONCLUSION

An unusual case of complete oblique compound fracture of radius and ulna in an Indian flying fox is discussed. Surgical anesthesia using ketamine and xylazine combination was effective in the present case. Surgical management of complete oblique compound fracture of radius and ulna in Indian flying fox can be performed effectively by intramedullary pinning. Successful rehabilitation post-therapeutic period is as important as the surgical procedure itself.

REFERENCES

1. Lewis, J.C.M, Storm, J. & Greenwood, A.G. (1993) Treatment of wing tip oedema in raptors. *Veterinary Record* 133, 328.
2. McLaughlin, A.B., Epstein, J.H., Prakash, V., Smith, C.S., Daszak, P., Field, H.E. & Cunningham, A.A. (2007) Plasma biochemistry and hematologic values for wild-caught flying foxes (*Pteropus giganteus*) in India. *J Zoo Wildl Med* 38(3), 446-52
3. Molur, S., Srinivasulu, C., Bates, P. & Francis, C. (2008) *Pteropus giganteus*. In: IUCN 2012. IUCN Red List of Threatened Species. Version 2012.2.
4. Newton, C.D. & Zeitlin, A. (1977) Avian fracture healing. *J Am Vet Med Assoc* 170(6), 620-625
5. Redig, P.T. (1998) Decision making in avian orthopedics. *Proc Assoc Avian Vet*, 253-263
6. Tangavelou, A.C., Rani, P.J. & Karthikeyan, S. (2013) Conservation of Sacred Indian flying fox (Bat) at sacred landscape of Pudukottai district, Tamil Nadu, India. *Asian Journal of Conservation Biology* 2(2), 178-180